

# Management of an Extruded Ventriculoperitoneal Catheter Coming Through the Umbilicus

Biodun Ogungbo, Olatunde Olawoye, Joy Ugochukwu Akudo, Peter Ebang

Department of Neurosurgery, Spine Fixed in Abuja, SFIA Spine Care Ltd, 15A Yawuri Street, Abuja, FCT, Nigeria

## Abstract

Ventriculoperitoneal shunts are useful devices for treatment of hydrocephalus. Although effective, historically, the probability of shunt dysfunction is pretty high throughout the life. Migration of a ventriculoperitoneal shunt catheter is a rare but well-recognised complication in hydrocephalus treatment. Perforation into different organs or through natural or artificial orifices has been described. A 5-month-old baby presented to hospital with extrusion of her abdominal catheter through the umbilicus. This occurred spontaneously 2 months following placement of a ventriculoperitoneal shunt for hydrocephalus. This is the first report of this unusual complication in Abuja, Nigeria.

**Key words:** Hydrocephalus, shunt, surgery

## CASE REPORT

A 5-month-old baby girl had a ventriculoperitoneal shunt (medium pressure valve of the Chhabra shunt) placed at 2 months of age. The baby had significant hydrocephalus manifested with sunset eyes, irritability, and poor feeding. Magnetic resonance imaging brain showed significant ventricular dilatation [Figure 1] and we proceeded with placement of the shunt. The 2 cm transverse abdominal incision was placed approximately 4 cm above the umbilicus. The wounds healed well and the baby was discharged without incident back to Port Harcourt, Rivers State.

Three months later, the mother noticed a cystic swelling around the umbilicus. The local general practitioner thought it was a pustule and commenced on antibiotic therapy (oral cefuroxime 125 mg 3 times daily). However, within 2 days, it got progressively bigger until the shunt protruded through it suddenly. The baby was therefore taken to the local district General Hospital in Port Harcourt for management [Figure 2].

The local pediatrician placed umbilical clamps on the catheter to stop continued egress of cerebrospinal fluid (CSF). The extruded catheter was cleaned, protected in sterile gauze with a bandage placed around the abdomen. A venous line was inserted and intravenous antibiotics were given. The baby was then referred to the neurosurgical unit in Abuja for definitive care. The preoperative blood showed that the white cell count

was significantly elevated. No radiological investigations such as a cranial computed tomography scan, abdominal X-rays were performed in this case.

We returned the baby to the theater and performed routine positioning, cleaning, and draping. The head wound was reopened and the ventriculoperitoneal shunt was disconnected. The abdominal catheter was pulled out through the umbilicus. The entire system was then removed, and the wounds closed. CSF and the shunt tip from the ventricular catheter were sent to the laboratory for microscopy and culture. The umbilical wound through which the shunt catheter had protruded was cleaned and closed with a single nonabsorbable suture.

Three days later, the culture reported that there were no organism and growth, clearing the way for a third operation to replace the shunt. The new shunt was placed on the opposite side of the head (left side). A separate abdominal incision was then created to access the peritoneum and a fresh abdominal catheter tunneled down from the cranial side. The shunt was reconnected and seen to be working well before re-implantation into the peritoneum.

**Address for correspondence:** Dr. Biodun Ogungbo,  
Spine Fixed in Abuja, Garki 2, Abuja, Nigeria.  
E-mail: ogungbo@icloud.com

This is an open access article distributed under the terms of the Creative Commons Attribution-NonCommercial-ShareAlike 3.0 License, which allows others to remix, tweak, and build upon the work non-commercially, as long as the author is credited and the new creations are licensed under the identical terms.

**For reprints contact:** reprints@medknow.com

**How to cite this article:** Ogungbo B, Olawoye O, Akudo JU, Ebang P. Management of an extruded ventriculoperitoneal catheter coming through the umbilicus. *Niger J Gen Pract* 2016;14:14-6.

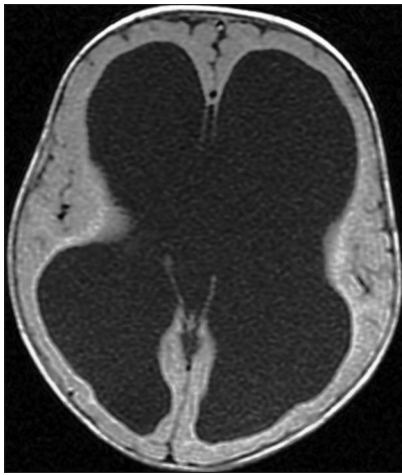
### Access this article online

#### Quick Response Code:



**Website:**  
www.njgp.org

**DOI:**  
10.4103/1118-4647.177534



**Figure 1:** The magnetic resonance imaging of the brain showing massive hydrocephalus

We continued antibiotic therapy until all the wounds were well healed. The baby was discharged uneventfully and reviewed 6 weeks later. At 6 weeks, she was thriving and no early complications were evident. The antibiotics used in her care were essentially cefuroxime 125 mg given 3 times a day along with Metronidazole infusion 100 mg 3 times a day intravenously for 5 days. Gentamycin injection 10 mg 3 times a day was also given intravenously for 6 days. On discharge, the baby was sent home on a week of the following antibiotics: Cefuroxime 125 mg and metronidazole 100 mg 3 times a day orally.

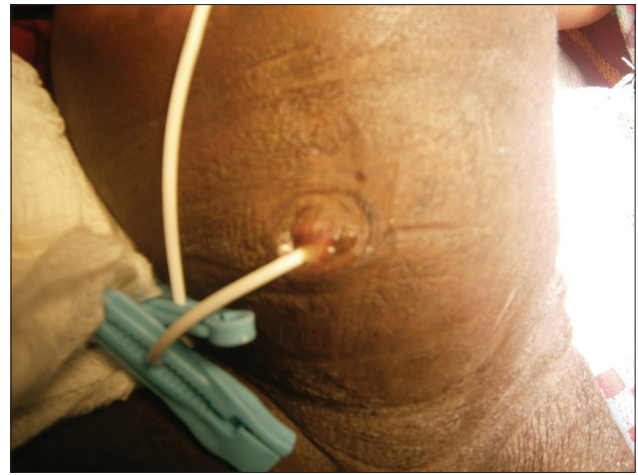
## DISCUSSION

Shunt migration has been reported all over the world and documented extrusions through unusual body parts such as the anus, brain, breast, mouth, into the heart, pulmonary artery, and vagina.<sup>[1,2]</sup>

Rare and potentially serious complications, such as migration of the peritoneal catheter into the pulmonary artery and the heart, have also been described in the literature.<sup>[3]</sup> The reason for catheter migration into the heart has been advanced by many. Migration of the distal catheter may occur through the internal jugular vein probably as the consequence of direct damage of the vessel during tunneling. Venous flow and negative intrathoracic pressure may then gradually pull the catheter up into the heart.<sup>[3]</sup>

Shunt catheters within the peritoneal cavity have migrated through and perforated almost all the intra-abdominal hollow viscera. Catheters have been reported to cause spontaneous perforation of the bowel.<sup>[4]</sup> Perforation of the bowel is a very rare complication occurring in <0.1% of cases. Although infrequent, this delayed complication can be fatal if it goes unrecognized.<sup>[4]</sup>

An article by Zhou *et al.*<sup>[5]</sup> describes a case of bowel perforation associated with a ventriculoperitoneal shunt inserted in an 8-month-old baby. Ten months after, the infant presented with the shunting tube protruding through the anus, without signs



**Figure 2:** The picture of the baby abdomen showing the extruded peritoneal catheter

of meningitis or peritonitis. At laparotomy, the tube was seen to enter the transverse colon and was encapsulated by the greater omentum. The tube was cut and the distal end removed via the anus. The transverse colon was repaired. The catheter continued to function effectively and the patient remained asymptomatic.<sup>[5]</sup>

Nakahara *et al.* reported migration through a cyst filled with CSF as reported in our case.<sup>[6]</sup> They attributed the migration to increased intra-abdominal pressure due to obesity, the use of a low friction hydrogel-processed peritoneal catheter, and the presence of a large dead space around the catheter.<sup>[6]</sup>

Studies of peritoneal dialysis models for the treatment of chronic renal failure patients provide important data about solute absorption in the peritoneal cavity and reactivity of the peritoneal membrane. This model suggests an inflammatory mechanism as the possible cause of perforation of the umbilicus.<sup>[7]</sup> Perforation through the umbilicus can become very complicated with an umbilical abscess and an infection as reported by others.<sup>[8]</sup> This did not happen in our patient perhaps because of early recognition and referral.

There are a very few reports of ventriculoperitoneal shunt operations reported from Nigeria. We had also performed over a hundred shunt operations usually without incident before this unforeseen situation. However, Morina *et al.* published a comprehensive report of the complications following shunt operations in a developing country.<sup>[9]</sup>

This is the first report of such a rare complication as we have described in Nigeria. It was clearly vital to reassure the family that although this case was unusual, it was not unheard of. The management in this case was successful and appeared straight forward. However, another management option would be to externalize the shunt, give antibiotic treatment, and perform delayed shunt reinsertion.<sup>[10]</sup> There is a small risk of infection with this strategy which was why we decided to remove the shunt completely and put in a fresh device on the opposite side.

## CONCLUSION

We have reported the first case of this unusual complication of ventriculoperitoneal shunts in Nigeria. The reason for the extrusion through the umbilicus was not clearly evident. The management was successful in this case.

## Financial support and sponsorship

Nil.

## Conflicts of interest

There are no conflicts of interest.

## REFERENCES

1. Lee BS, Vadera S, Gonzalez-Martinez JA. Rare complication of ventriculoperitoneal shunt. Early onset of distal catheter migration into scrotum in an adult male: Case report and literature review. *Int J Surg Case Rep* 2015;6C: 198-202.
2. Sharma RK, Bansal M, Agrawal M, Gupta A, Sinha VD. Complete intracranial migration of a ventriculoperitoneal shunt: Rare complication of a common procedure. *Neurol India* 2015;63:106-7.
3. Nguyen HS, Turner M, Butty SD, Cohen-Gadol AA. Migration of a distal shunt catheter into the heart and pulmonary artery: Report of a case and review of the literature. *Childs Nerv Syst* 2010;26:1113-6.
4. Sathyanarayana S, Wylen EL, Baskaya MK, Nanda A. Spontaneous bowel perforation after ventriculoperitoneal shunt surgery: Case report and a review of 45 cases. *Surg Neurol* 2000;54:388-96.
5. Zhou F, Chen G, Zhang J. Bowel perforation secondary to ventriculoperitoneal shunt: Case report and clinical analysis. *J Int Med Res* 2007;35:926-9.
6. Nakahara K, Shimizu S, Oka H, Utsuki S, Iida H, Fujii K. Migration of the distal end of a ventriculoperitoneal shunt into the abdominal wall in an obese patient: Case report. *Neurol Med Chir (Tokyo)* 2009;49:490-2.
7. de Aquino HB, Carelli EF, Borges Neto AG, Pereira CU. Nonfunctional abdominal complications of the distal catheter on the treatment of hydrocephalus: An inflammatory hypothesis? Experience with six cases. *Childs Nerv Syst* 2006;22:1225-30.
8. Silav G, Tun K, Dolgun H, Unlu A, Selcuki M. The spontaneous umbilical perforation of the distal end of ventriculoperitoneal shunt. *Neurochirurgie* 2002;48:128-30.
9. Morina Q, Kelmendi F, Morina A, Morina D, Bunjaku D. Ventriculoperitoneal shunt complications in a developing country: A single institution experience. *Med Arch* 2013;67:36-8.
10. Gupta A, Ahmad FU, Kumar A, Gaikwad S, Vaishya S. Umbilical CSF fistula: A rare complication of ventriculoperitoneal shunt. *Acta Neurochir (Wien)* 2006;148:1205-7.